

Non-Prolapsing Total Defunctioning Transverse Loop Colostomy

YASIR S. JAMAL, FRCS(1), FICS

*Department of General Surgery, Faculty of Medicine & Allied Sciences,
King Abdulaziz University, Jeddah, Saudi Arabia*

ABSTRACT. Transverse loop colostomy is a simple procedure in its construction and closure. Prolapse is a common complication of this procedure. Occasionally, total defunctioning may not be achieved with loop colostomy.

In the present study, a simple modification of loop transverse colostomy which is prolapse free and gives total defunction is described.

Keywords: Non-prolapsing transverse loop colostomy, Children.

Introduction

Colostomy, which is sometimes necessary to relieve distal colonic obstruction or to protect the distal colonic or rectal anastomosis, is sometimes unavoidable.

Due to the medical complications of colostomy and its social disadvantages, modern literature with increasing frequency has described alternative methods in its management^[1-4]. While some surgeons are trying to use these alternatives, others are trying to reduce the complications associated with the colostomy by modifying the technique^[5-11]. Prolapse is a common complication, modified techniques were described to prevent it, some of them are simple and others are difficult during construction or closure of the stoma. In the present study, a new surgical modification of loop transverse colostomy which protects against prolapse and achieves total defunctioning of the distal colon in 20 patients is described. The principle of this technique will be discussed.

Patients and Methods

Twenty patients were in need of a colostomy for different reasons: 13 patients with Hirschsprung's disease, 6 anorectal malformation, 1 with Necrotizing Enterocolitis. All

Correspondence & reprint requests to: Prof. Yasir S. Jamal, PO Box 6615, Jeddah 21452, Saudi Arabia.
Accepted for publication after revision 14, January 1997. Received 14th November 1996

patients had transverse loop colostomy, the youngest was 2-days old and the eldest was 14 years old. The duration was from 6 weeks to 11 months. The principles of the modification in performing the non-prolapsing loop transverse colostomy with total defunctioning are based on the following:

1. Reducing the redundancy of the transverse colon. Prolapse of a transverse colostomy is primarily due to redundancy of the transverse colon. This redundancy can be reduced by suturing the afferent and efferent limbs of the colon together at the proposed site of the colostomy, which has the additional advantage of securing the more commonly prolapsing distal limb (Fig. 1).

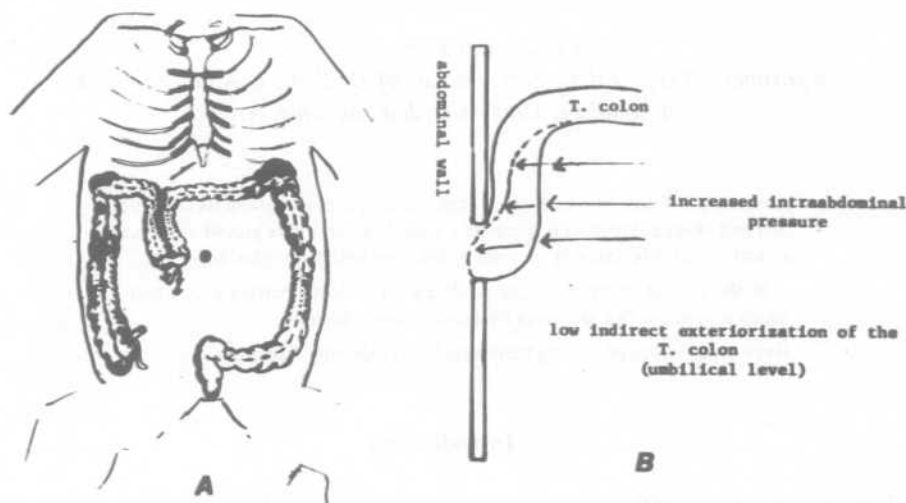


FIG. 1 Diagram (a) showing the umbilical level stoma with application of the transverse colon. Arrow shows the effect of the low position of the stoma in total defunctioning of the distal colon. (b) lateral view explaining the valve mechanism of prevention of the prolapse during the increase intra-abdominal pressure.

2. Low siting of the stoma. Locating the stoma below the normal course of the transverse colon at the umbilical level of the mid-clavicular line will prevent the end on view of the afferent and efferent stomas. Consequently, the increased intra-abdominal pressure will push the approximated limbs against the abdominal wall acting as a valve to prevent the prolapse of the colon (Fig. 1). This is in contrast to the usual transverse colostomy where the colon is directly exteriorized along the normal course of the transverse colon in the right upper quadrant. The increased intra-abdominal pressure will exert direct pressure pushing the colonic wall to the exterior (Fig. 1). This indirect exteriorization of the colon at the umbilical level leads to total defunctioning of the distal colon as it is not feasible for the effluxed stool from the proximal stoma to pass to the distal colonic lumen against gravity (Fig. 1). In contrast to the upper quadrant transverse loop colostomy where the end on opening of the two adjacent stomas of the loop makes it easy for effluxed stool from the proximal end to spill over to the distal end aided by gravity (Fig. 2).

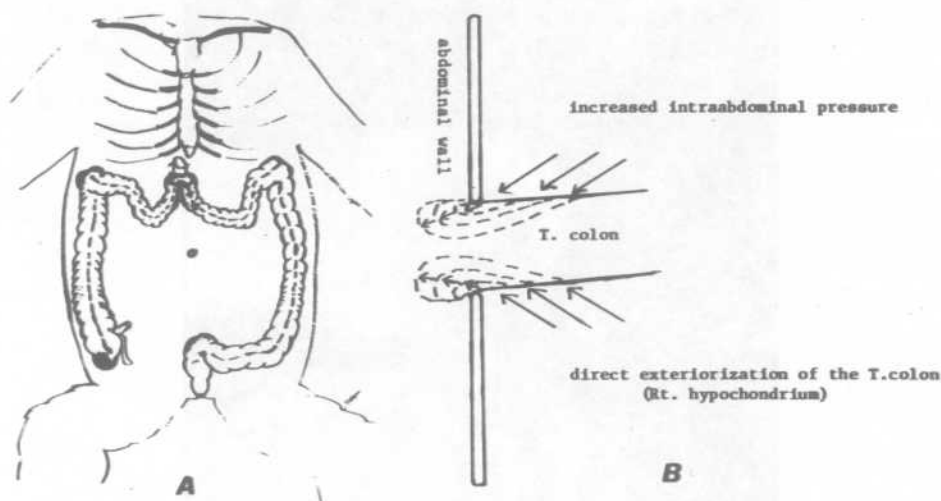


FIG. 2 The upper quadrant transverse colostomy. The diagram indicating the easiness of the direct prolapse of the stoma with the increase of the intra-abdominal pressure. Arrows indicate the spill over to the distal colon with the possible effect of the gravity on the incomplete defunctioning of the distal colon.

Operative Steps. A through transverse incision 3-5 cm long was done centered at the mid-clavicular line at the level of the umbilicus. The transverse colon is identified and fully pulled through the wound to check its redundancy (Fig. 3). Approximating non-absorbable stitches are applied to the two adjacent limbs of the exteriorized transverse colon (Fig. 4). The ideal site of the colostomy is at the junction of the right third with the left two thirds of the transverse colon to avoid restricted mobilization of the distal colon during the pull through procedure. The stoma is fixed to the abdominal wound according to the diameter of the required stoma using a bridging plastic tube to maintain the colostomy above the level of the skin. The tube is usually removed after one week. This modification did not prolong the operative time. To evaluate the total defunction of the distal colon clinically, the mothers were regularly asked if the child is passing stool or mucous per rectum. The total defunction was also tested in two patients by radioactive procedure. Technicium labelled colloidal radioactive substance was injected into the proximal colon and the bag is reapplied. After 24 hours the distal colon was washed out with saline and the collected material was scanned for any radioactivity.

Results

None of the twenty patients who had this technique had any prolapse during the entire period until closure of the colostomy. Stool was not passed per rectum in any patient but mucous was occasionally passed. The two patients who were tested with colloidal radioactive isotope showed no radioactivity in the washout fluid of the distal colon.

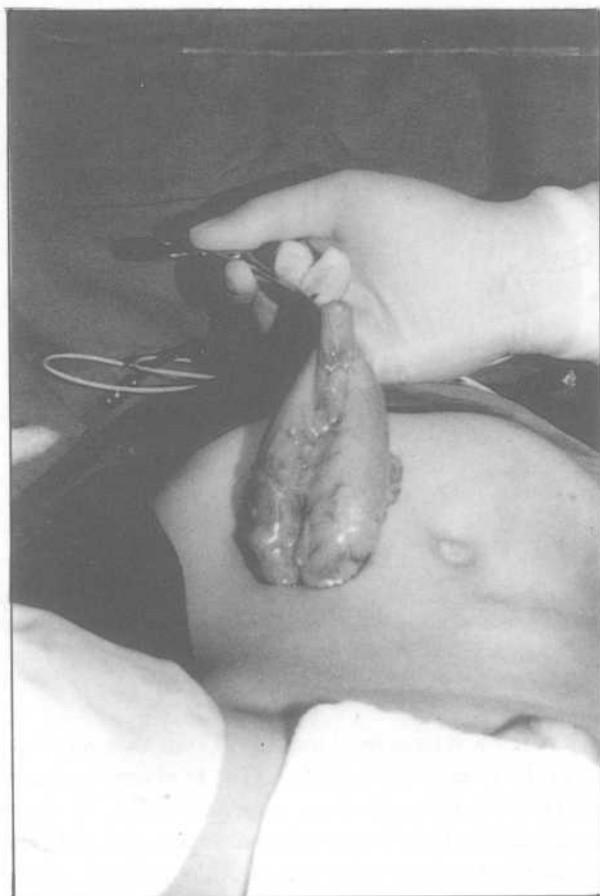

FIG. 3 Withdrawal of the transverse colon to identify the degree of redundancy of the transverse colon.

Discussion

Loop colostomies prolapse are more common than the end colostomies, and the prolapse is commoner in children than in adults. Loop colostomy is preferred as it is easy to construct and to close. On the other hand, it is associated with more complications than end colostomies particularly prolapse and incomplete defunctioning^[12-20].

Several modifications of the transverse colostomy were reported to prevent^[5-11] or treat^[21-27] the prolapse and to achieve total defunction of the distal colon^[28-32]. Some were based on total closure of the distal stoma or narrowing it by the purse string or stenting of the lumen^[5-11].

The presented technique is a simple modification of the classic easy transverse loop colostomy. The idea is based on avoiding direct exteriorization of the colon and reducing its redundancy without any division or excision. Such modification has not been reported before. Majano *et al.* reported their experience in adults, performing a trans-

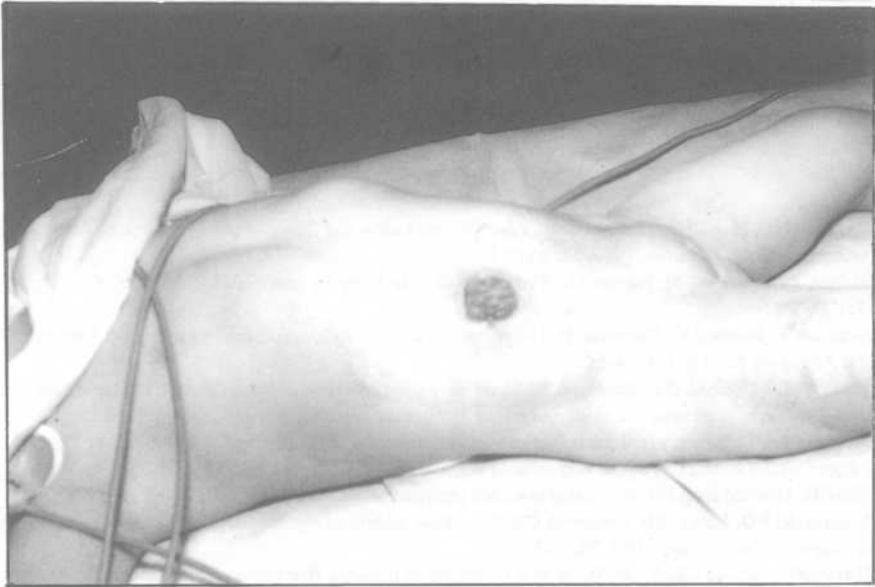

FIG. 4 At the time of closure of the umbilical level transverse colostomy after 11 months of having the stoma (good site for the application of the colostomy bag).

verse colostomy in the right iliac fossa; they indicated that it is not mandatory to construct the transverse colostomy at the right upper quadrant but to choose the optimum site for each patient^[33].

I believe that the lower the level of the transverse loop colostomy the less the possibility of prolapse, as there will not be much redundancy of the transverse colon to permit prolapse. Suturing of the redundant loop limbs of the transverse colon, will reduce the need for very low level stoma as seen in our patients with umbilical level stomas.

The efficacy of loop colostomy in defunctioning of the distal bowel is controversial^[30]. On the other hand, the divided loop colostomy or loop colostomy with closure of the distal stoma will give total defunction^[5,28,31,32]. The present modification gives similar total defunction without the need to divide the colon or to close the distal end as the spilled over stool cannot pass against gravity to the distal lumen of the colostomy. Both openings of the stoma are placed in a low caudal dependent position at a level lower than the main course of the transverse colon, thus there will be no contamination of the distal bowel (Fig. 1A). Some surgeons modify their technique utilizing the effect of the gravity in preventing the contamination of the distal colon by rotation of the stoma 90°^[34] or by siting the proximal stoma caudally^[35], both modifications make the proximal stoma in a dependent position and the distal stoma in non-dependent one.

The suggested stoma is of a good site for sitting the colostomy bag as it is away from skin creases or bony prominences (Fig. 4).

In conclusion, the umbilical level transverse loop colostomy with application of the redundant transverse colon is a simple modification of the usual transverse loop co-

lostomy that gives a non-prolapsing stoma with total defunction of the distal colon without the need to divide the colon or close its distal stoma. The suggested stoma site is more suitable site for adhesive and non-adhesive stoma appliances than the standard site.

References

- [1] Pachter HL, Hoballah JJ, Corcoran TA. The morbidity and financial impact of colostomy closure in trauma patients. *J Trauma* 1990; 30: 1510-1513.
- [2] Hagen J, Deitel M, McIntyre JA. Avoidance of colostomy by nutritional techniques. *Int Surg* 1986; 71: 32-35.
- [3] Vixman F, Ionescu C, Volkmar P. The unopened colostomy: A procedure to protect coloanastomosis. *Int J Colorect Dis* 1993; 8: 48-50.
- [4] Renz BM, Feliciano DV, Sherman R. Some admission colostomy closure (SACC). A new approach to rectal wounds: A prospective study. *Ann Surg* 1993; 218: 279-292.
- [5] Nasymyth DG. Stoma in colorectal surgery; options and alternatives. *Dig Dis* 1990; 8: 240-252.
- [6] Light HG. A secure end colostomy technique. *Surg Gynecol Obstet* 1992; 174: 67-68.
- [7] Ein SH. Divided loop colostomy that does not prolapse. *Am J Surg* 1984; 147: 250-252.
- [8] Fitzgerald PG, Lau GYP, Cameron GS. Use of the umbilicus site for temporary colostomy: Review of 47 cases. *J Pediatr Surg* 1989; 24: 973.
- [9] Narasimharo KL, Chaterjee H. A new technique of prolapse free transverse colostomy. *Surg Gynecol Obstet* 1984; 158: 283.
- [10] Golladay E, Bernay F, Wagner C. Prevention of prolapse in pediatric enterostomies with purse string technique. *J Ped Surg* 1990; 25: 990-901.
- [11] Lau JTK. Proximal end transverse colostomy in children: A method to avoid colostomy prolapse. *Dis Colon Rectum* 1983; 26:221-222.
- [12] Mollitt DL, Malangoni MA, Ballantine TVN, Grosfeld JL. Colostomy complications in children. *Arch Surg* 1980; 115: 455-458.
- [13] Lister J, Webster PJ, Mirza S. Colostomy complications in children. *The Practitioner* 1983; 227:229-237.
- [14] Nixon HH. Paediatric problems associated with stomas: Part I Intestinal Surgical procedure. *Clinic Gastroenterol* 1982; 11: 351-359.
- [15] Abcarian H, Pearl R. Stomas. *Clin N Am* 1988; 68: 1295-1305.
- [16] MacMahon RA, Cohen SJ, Eckstrin HB. Colostomies in infancy and childhood. *Arch Dis Child* 1963; 38: 114-117.
- [17] Keeley JL. Prolapse of efferent (distal) segment of bowel after colostomy. *Surg Gynecol Obstet* 1942; 75: 605-611.
- [18] Chandler JG, Evans B. Colostomy prolapse. *Surgery* 1978; 84: 577-582.
- [19] Alterescu KB. Colostomy. *Nurs Clin N Am* 1987; 22: 281-219.
- [20] Waninger J, Leititis J, Russler S. Temporary stoma in infancy and childhood. *Zentralbl Cheir* 1991; 116: 663-668.
- [21] James TK, Lau H, Asin G, Ong GB. Double purse string technique for loop colostomy prolapse in infants. *Aust Paediatr J* 1982; 18: 58-59.
- [22] Fucini C. A simple device for prolapsing loop colostomies. *Dis Colon Rectum* 1989; 32: 534-535.
- [23] Gandener MWL, Izant RJ. A technique for temporary control of colostomy prolapse in children. *J Pediatr Surg* 1985; 20: 653-655.
- [24] Abdulatif AM, Sherman IW, Fiddian RV. D'elorme operation for prolapsed colostomy. *Br J Surg* 1989; 76: 1321-1322.
- [25] Moghner JG, Siplovich I, Roda H, Cywes S. Bedside modified latex tube colopexy for the treatment of colostomy prolapse in children. *Isr J Med Sci* 1990; 26: 410-411.
- [26] Berzin S, Gerding H, Giranda RMA. Button colopexy for colostomy Prolapse. *S Afr J Surg* 1988; 26: 73-74.
- [27] Krasna IH. A simple purse string suture technique for treatment of colostomy prolapse and intussusception. *J Pediatr Surg* 1979; 14: 801-802.

- [28] Merrett ND, Fartell PC. A totally diverting loop colostomy. *Ann R Coll Surg Engl* 1993; 75: 272-274.
- [29] Fontes B, Fontes W, Utiyama EM, Birolini D. The efficacy of loop colostomy for complete fecal diversion. *Dis Colon Rectum* 1988; 31: 298-302.
- [30] Morris Dm, Rayburn D. Loop colostomies are totally diverting in adult. *Am J Surg* 1991; 161: 668-671.
- [31] Allende DA, Charcoles R, Eynard H. Defunctioning lateral colostomy or ileostomy. *Dis Colon Rectum* 1987; 30: 300-302.
- [32] Ngakane H, Luvuno F. Technical aids in surgery. Completely defunctioning loop colostomy. *S Afr J Surg* 1989; 27: 145-146.
- [33] Majno PE, Lees VC, Goodwin K. Siting a transverse colostomy. *Br J Surg* 1992; 79: 576-577.
- [34] Heslop JF, Keddie NC, Isbister WH. Defunctioning colostomy in the management of colovesical colovesical fistula: a simple technique. *Br J Surg* 1986; 73: 623-624.
- [35] Schofield PF, Cad D, Lambert M. Dependent proximal loop colostomy: Does it defunction the distal colon? *Br J Surg* 1980; 67: 201-202.

تفميم عروة من القولون المستعرض لا يتصاحب بتدلي القولون ويبعد البراز كلياً عن القولون الأقصى للتفميم

ياسر جمال

قسم الجراحة العامة ، كلية الطب والعلوم الطبية ، جامعة الملك عبد العزيز
جدة - المملكة العربية السعودية

المستخلص . تتميز عملية تفميم عروة من القولون المستعرض بسهولة عند التفميم وعند الإغلاق . يعتبر تدلي القولون من المضاعفات الشائعة لهذا التفميم وقد لا يحقق الإبعاد الكامل للبراز عن القولون الأقصى للتفميم . هذه الدراسة توضح تحوير بسيط لتفميم عروة بالقولون المستعرض أثبتت جداولها في منع حدوث التدلي وفي الإبعاد الكامل للبراز عن القولون الأقصى للتفميم .