

20 - 22 September 2004 / 6 - 8 Shaban 1425

Minimally Invasive, Laparoscopic, Robotic

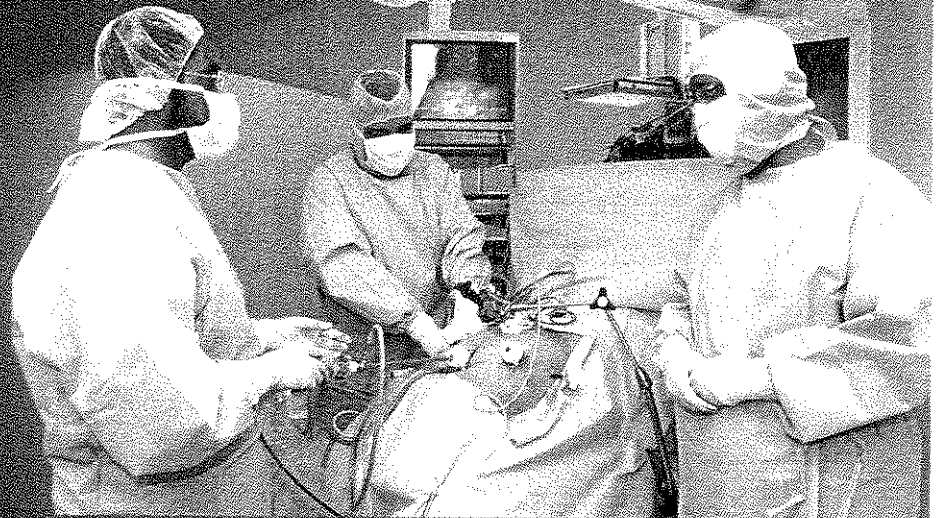


# SURGERY


*Surgery of the 21st Century*



Accredited by the  
American Academy of  
Continuing Medical Education



## ABSTRACT BOOK



### INFORMATION:

Academic & Training Affairs, CME Section, King Faisal Specialist Hospital and Research Centre  
P.O. Box 3354, MBC - 36, Riyadh 11211, Kingdom of Saudi Arabia

Tel. No.: +966-1-442-7238 / 442-4858 • Fax No.: +966-1-442-4153 • Email: [web\\_symposia@kfshrc.edu.sa](mailto:web_symposia@kfshrc.edu.sa)



**LAPAROSCOPIC TREATMENT OF LIVER HYDATID CYST USING LIPOSUCTION MACHINE**

**Prof. Zain Al Shareef, MD**  
(and Mohammed Al Harbi, MD)  
King Faisal Specialist Hospital & Research Centre  
Jeddah, Saudi Arabia

Hydatid disease is endemic in the Arabian Peninsula. Liver is the commonest organ affected by the hydatid cyst. While surgery is the operative method of choice laparoscopic surgery for hydatid cyst is now feasible and successful.

Fourteen hepatic hydatid cysts are treated by laparoscopic technique. All received Albendazole 10 days preoperatively and 6 weeks postoperatively. The technique involves aspiration of cyst fluid, injection of the cyst with Betadine 10% for 10 minutes, aspiration of contents of the cyst including scolices daughter cysts and endocysts by liposuction machine, which has never been reported in the literature. All techniques were carried out with three 10 mm ports. Subsequently, the ectocyst around the port site was partially excised and a drain left outside the cyst, which was removed after 48 hours.

Ten patients had single large cysts in the right lobe of liver and two patients had two cysts in each lobe of the liver. All cysts were treated without any complications. All patients were discharged on the fifth postoperative day. The cases reported in these series were followed up by periodic ultrasonography and CT scan. Most of the cysts healed completely after two months.

In conclusion: laparoscopic treatment of liver hydatid cysts is advantageous having less postoperative pain, no ileus, short hospital stay and quick return to full recovery. We describe for the first time the use of liposuction machine in laparoscopic treatment of hepatic hydatid disease.