

## Circumcision: A Safe and Adequate Technique

JAMAL S.D. AL-RAHMAN, FRCS(I), OSAMA M. RAYES, FRCS(I),  
SABAH S. MESHREF, FRCS(I) and YASIR S. JAMAL, FRCS(I), FICS  
*Department of General Surgery, Faculty of Medicine & Allied  
Sciences, King Abdulaziz University, Jeddah, Saudi Arabia*

**ABSTRACT.** Circumcision is a routine procedure in our community for all males for a religious purpose. The majority are done in the neonatal period. For the first time in Saudi literature we established in our hospital a criteria for adequate circumcision and recommended guidelines to achieve these criteria which proved to be effective in performing satisfactory circumcision. We modified the technique to achieve further ease in adjusting the appropriate preputal level of cut without fear in injuring the glans penis, which we found to be of concern to the junior practitioner, particularly in babies in the lower range of normal penile length. This modification was applied to the circumcision of 1188 male infants circumcised over a period of four years aiming at a safe, adequate, and easily applicable procedure even for junior staff to do with basic available instruments.

**Keywords:** Circumcision, Technique.

### Introduction

Circumcision is one of the oldest surgical procedures known in medical history as early as more than 6,000 years. It was reported that Prophet Abraham performed it for himself; it was also seen in the drawings in ancient Egyptian temples and recognized in their mummies[1-3).

Al-Zahrawi, a known muslim physician in the 3rd century A.H., was the first to describe the procedure by the dissection technique and pointed out its complications and how to handle them[4]. Various techniques are used in circumcision including the dissection method, which is the oldest and still in practice. Other techniques are utilizing

---

Correspondence & reprint requests to: Dr. J.S.D. Al-Rahman, P.O. Box 6615, Jeddah 21452, Saudi Arabia.  
Accepted for publication: 25 February 1998. Received: 23 December 1996.

the straight forceps or circumferential clamps (gomco and plastibil). None of these described techniques are without complications, but each technique carries its advantages and disadvantages.<sup>10</sup> The criteria for adequacy are to have clearly uncovered glans with an adequately covered penile shaft and a healed paracoronary wound. The guidelines to achieve this using a straight forceps, which we described previously, was of satisfactory outcome.<sup>10</sup> However, some colleagues were concerned about the possibility of injuring the glans penis. This fear leads to reluctance of our junior staff to cut the foreskin at its optimal level which results in inadequate circumcision. To avoid major, but rare, complications, slight modifications were recommended and were applied on 1,188 male babies.

In the present study the main objective is to present this modification and to reconfirm the efficacy of our guideline in performing an adequate and safe circumcision.

### Materials and Methods

1,188 infants were circumcised by the following technique under local anaesthesia as an outpatient procedure. Sixty-five (65) babies were between one and three months of age, the rest (1,123 babies) were below one month. Ninety-one percent (91%) of them were within the first week of life. The procedures were done after comfortably restraining the baby on the special circumcision board and under complete aseptic conditions as follows:

Step 1: Injection of 0.5 ml xylocaine 1% (w/v) plain (penile dorsal nerve block, Kirya technique)<sup>11</sup> with circumferential infiltration of another 0.5 ml at the base of the penis. No marking of the optimal level of the cut to be made at this stage. Step 2: Five minutes later, gentle separation of the prepuce from the glans until the corona, with cleaning of retained smegma. Step 3: Application of two mosquito forceps to the ventral and dorsal midline, pulling the prepuce forward and sliding the glans with the left index and thumb backward before applying the bone cutting forceps. Then the foreskin cut flushed on the bone cutting forceps. This will remove a small piece of foreskin separating the outer skin of the prepuce from the inner mucosal layer. Step 4: The prepuce then turned back to the corona and three mosquito forceps then applied to the inner layer of the foreskin (a dorsal and two on either side of the ventral midline). This layer is cut between these three forceps, leaving an inner layer rim of 2-3 mm for the corona. Step 5: After marking the appropriate level of cut, the glans can be slid proximally in the sleeve of penile skin leaving the extra foreskin to be excised to the marked level without any risk of injury to the glans, leaving adequate skin to cover the penile shaft. This is the main difference from our technique previously reported (Figs. 1). Step 6: Haemostasis maintained using diathermy coagulation precisely for the bleeding points and interrupted circumferential sutures then applied to close the incision edges (two midline and two on either side). The wound is then dressed with soft gauze, dry gauze, and adhesive plaster with minimal pressure. The parents are instructed to remove the dressing 24 hours later after saline soaking, saline wash every time the nappy has to be changed for three days, and to come for review after one week.

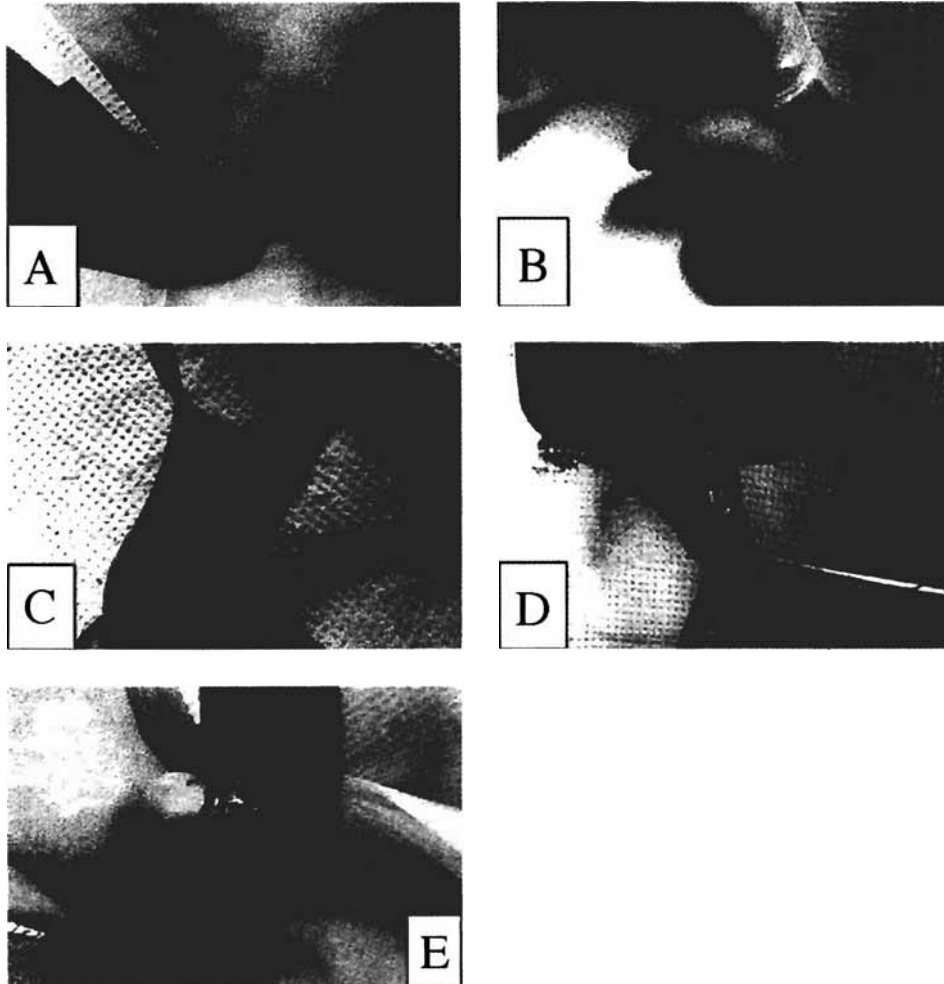


FIG. 1. Plate A: Preoperative view.

Plate B: Mark level of the first cut of the small rim of the prepuce to facilitate the separation of the top layers of the prepuce.

Plate C: The marking of the second cut at the appropriate level with easily pushed back glans after separation of the two layers of the prepuce.

Plate D: The shaft of the penis covered adequately.

Plate E: Final appearance showing the satisfactory circumcision with uncovered glans penis and adequately covered shaft.

## Results

On evaluating our technique, we noticed the following: 1) Ten babies cried on applying the clamps and were irritable; 2) Bleeding was noticed in one case only. This presented three hours after the procedure. There was oozing from the cut margin and no active bleeding was identified. The bleeding stopped after the change of dressing and an application of tincture benzoin. Coagulation study of this child was within normal range; and 3) At follow-up one week later, only 825 babies (69.4%) attended; the rest (30.6%) failed to attend postoperative follow-up. Of those who attended, 15 babies (1.8%) developed fibrinous glanuloperpetual adhesions which were released by a blunt probe in the clinic. The rest had acceptable cosmetic results according to our criteria. No other complications were seen and no re-circumcision had to be done during the present study.

## Discussion

Circumcision is a routine procedure for males in the muslim community and in our community it is done early in the neonatal period. Despite the fact it is practiced since Father Abraham 6000 years ago[1-4]. The majority of them are preventable but still being reported in our community and worldwide regardless of the techniques used, probably as a result of underestimating it as a minor procedure[5-15]. One of these is reported where we find unsatisfactory results in 54.9% of the screened group including cases were performed by the medical professionals. In spite of the satisfactory results which we achieved by applying our guidelines we continue to evaluate these guidelines in trial to improve them so we introduce the modification which was based on freeing the two layers of the prepuce by trimming a rim of the distal prepuce to free the glans and the penile shaft from the penile skin. This separation makes it easy and safe to cut the prepuce at the desired level with the glans slide back in the sleeve of penile skin. Additionally, this separation makes it more accurate to establish the required skin necessary to cover the stretched penile shaft which is an important step to prevent the under- or overestimation of the level of cut that might necessitate re-circumcision or correction or the shortage of skin by skin grafting, respectively.

The present study is a continuation of our experience which reconfirmed to us the efficacy of our guidelines in performing a satisfactory circumcision by the satisfactory results obtained in 99.8% and 99.7% in our previous[10] and present studies, respectively. Al-Bar, in his published book of circumcision, stresses the importance of the guidelines which we recommended[16].

In the present study, the 15 cases (1.8%) of the glanulopreputal adhesions, which was seen in the babies who attended their follow-up visits, indicate the importance of the post-circumcision follow-up to treat this preventable complication which can be managed easily at the fibrinous adhesive stage rather than to be managed when it has become established fibrous, adhesions requiring surgical release under general anaesthesia.

In conclusion, this study reconfirmed the validity of the guidelines which we suggested previously[10] in producing a satisfactory circumcision. At the same time, the

presented modification makes the practice of circumcision by using the straight clamp safer and easier, particularly to the junior doctors.

#### References

- [1] Warna P. Historical review: circumcision. *Arch Pediatr* 1939; 56: 385-392.
- [2] Adams F. In: *Seven books of Paulus Aegineta*. Translated by Adams F. Vol 2. London: Sydenham, 1846.
- [3] Abdel Halim RE. Paediatric urology 1000 years ago. *Progress in paediatric surgery*. Vol 20. Berlin, Heidelberg: Springer-Verlag, 1986.
- [4] Al Zahrawi A. Al tasreef le-rnanajeza an al ta-al-leeef, 13th century. Arabic Manuscript. Section 53, Circumcision and its complications. Vol. 30,99-102 (Microfilm 3172 f. Al-Iman bin Saud University Library, Riyadh, Saudi Arabia)
- [5] Grimes C. Routine circumcision of the newborn infant: a reappraisal. *Am J Obstet Gynecol* 1998; 130: 125-129.
- [6] Speert H. Circumcision of the newborn. *Obstet Gynecol* 1953; 2: 164-171.
- [7] Gee WF, Ansell JS. Neonatal circumcision. A ten years overview with comparison of Gomco clamp and plasitbell device. *Pediatrics* 1976;58: 824-827.
- [8] Shalman J, Ben-Hur N, Newman Z. Surgical complication of circumcision. *Am J Dis Child* 1964;107: 149.
- [9] Patel H. The problems of routine circumcision. *Can Med Assoc J* 1996; 576: 95.
- [10] Jamal YS, Eed MD, Meccawi AA, Ashy AA, Meshreh SSe Critical evaluation of circumcision in the western region, Saudi Arabia. *J KAU Med Sci* 1994; 1: 37-48.
- [11] Kirya C, Werthmann MW. Neonatal circumcision and penile dorsal nerve block. A painless procedure. *J Pediatr* 1998; 92: 998-1000.
- [12] Perley JM, Shapiro S. Complications of circumcision. In: De Veries PA, Shapiro S, eds. *Complications of pediatric surgery*. New York: Wiley Medical Publications, 1982;475-481.
- [13] Sterenberg N, Golan J, Ben-Hur N. Necrosis of the glans penis following neonatal circumcision. *Plast Reconstr Surg* 1981;68: 237-239.
- [14] Lau JTK, Ong GB. Subglanular urethral fistula following circumcision repaired by the advancement method. *J Urol* 1981;126: 702-703.
- [15] Kaplan GW. Complications of circumcision. *UroJ Clin North Am* 1983; 10: 543-549.
- [16] Al-Bar MA. Methods of circumcision and the complications: circumcision. Edited by: Dar Al Manara, Jeddah, 1994; 103-109.

## الختان : طريقة مأمونة وسليمة

جمال دليل 1(حمن , أسامة ريس , صباح مشرف , وياسر جمال  
قسم الجراحة العامة , كلية الطب والعلوم الطبية , جامعة الملك عبدالعزيز ,  
جدة , المملكة العربية السعودية

المستخلص . إن ختان الذكور من العمليات الاعتيادية التي تجرى في مجتمعنا وذلك لأسباب دينية وغالباً ما يتم ذلك في المهدي . وفي مستشفى جامعة الملك عبدالعزيز بجدة تم وضع أسس ومعايير للختان المقبول ووضعت الخطوات اللازم إتباعها للحصول على هذه المعايير وتم نشرها لأول مرة على مستوى المدونات الطبية السعودية في هذه المجلة في عام ١٩٩٤م ' في هذا البحث تم إجراء تعديل طفيف على هذه الخطوات وذلك بهدف تبسيط العملية وإزالة التخوف من قطع الحشفة والتي كثيراً ما تعيق المبتدئين . تم تطبيق هذا التعديل عند ختان ١٨٨ طفلاً على مدى أربع سنوات وكانت النتيجة هي الوصول إلى طريقة سليمة وسهلة ومأمونة ترضى الأسس والمعايير السابق وضعها وخاصة عندما تجرى من قبل المبتدئين وبالأدوات المتوفرة في أى عيادة جراحية .